ScieniQ Publishers

Japan Journal of Medical Science

Case Report

Pyoderma Gangrenosum in the Presence of Coronavirus Disease (COVID-19)

Kinari Xina Patel MBChB, Mohammed S Al Abadie PhD FRCP

Department of Dermatology. The Royal Wolverhampton NHS Trust. United Kingdom

Corresponding author
Mohammed Al Abadie, Department of Dermatology, Royal Wolverhampton NHS Trust, Wednesfield Road, Wolverhampton, West Midlands, WV10 0QP, UK

Received: 17 Feb 2021
Accepted : 20 Feb 2021
Published: 20 Mar 2021

Abstract
Pyoderma gangrenosum is an inflammatory disorder which is commonly linked to conditions such as irritable bowel disease and rheumatoid arthritis. It typically presents on the lower legs and follows a pattern of rapid progression from small pustules or papules to large gangrenous wounds [1]. Management depends on the severity of the presenting lesions, but in general involves the use of prednisolone or ciclosporin, alongside optimal wound care and analgesia. We are reporting the possible association of pyoderma gangrenosum to COVID-19.

Signs
- Papules in the early stages
- Ulcer with necrosis
- Classic "violaceous border"
- Evidence of pathergy
- Intensely painful
- Rapid growth and spread

Aetiology
The pathophysiology underlying pyoderma gangrenosum is not very well defined, however it is currently understood to be linked with heavy neutrophil involvement and disease processes such as pathergy.

Diagnosis
Pyoderma gangrenosum is largely considered a clinical diagnosis, as it is usually identified through the appearance, evolution and progression of the lesion. However, there are a few key existing tools that are currently used in the diagnostic process.

Keywords: Pyoderma gangrenosum, COVID-19, pathergy, autoinflammatory

Introduction
Pyoderma gangrenosum is a rare disease of inflammatory nature, most commonly seen to be classified as a type of "neutrophilic dermatosis" [1]. The aetiology still remains unclear, but existing research suggests an underlying autoinflammatory disease process strongly linked with dense neutrophilic involvement. Below we report a male patient who presented with a large pyoderma gangrenosum, with no significant co-morbidities of note, apart from asthma. We discuss the relationship between this skin lesion and a coinciding diagnosis of coronavirus (COVID-19) and explore the management techniques used to treat the patient. No previous reports of a link between coronavirus and pyoderma gangrenosum have been identified in existing literature.

Aetiology of Pyoderma Gangrenosum
Pyoderma gangrenosum usually presents as a rapidly growing skin lesion. A typical history might involve the progression of the lesion from a small pustule or papule to a deep, ulcerating wound with a distinct 'violaceous border', within a short space of time. Another key feature of note is the relationship between pyoderma gangrenosum and the skin manifestation of 'pathergy'. This term describes a process whereby a wound worsens or transforms into an ulcer, when subjected to a relatively minor injury [2]. This response is inappropriate relative to the level of trauma inflicted.

This autoinflammatory condition tends to present in patients who have other underlying medical conditions such as rheumatoid arthritis, ulcerative colitis and haematological malignancies such as leukaemia. The specific underlying aetiology remains undefined, but literature suggests that neutrophils are a key aspect of the disease process.

Association with viral infections

Upon extensive review of literature, there is no clear evidence to suggest viral infections as a cause of pyoderma gangrenosum, however it is clear that ruling out viruses as a differential diagnosis for this condition is part of the diagnostic pathway.

Pyoderma Gangrenosum and COVID-19

There are currently no reports of a direct link between SARS-CoV-2 infection and the development of pyoderma gangrenosum, but the case report below suggests that there might be a potential association given the underlying inflammatory aetiology of pyoderma gangrenosum. This link is not definitive, the case is just suggestive of an interesting connection between the two diseases.

Histopathology

Histology can vary depending on factors such as the type of pyoderma gangrenosum and the stage of disease at which the biopsy was obtained. Nonetheless, common findings include heavy neutrophilic involvement, oedema involving the dermal layer, ulceration and abscesses [3]. Early on, heavy infiltration of inflammatory cells within the dermis tends to be common, followed by evidence of ulceration and abscesses involving the epidermis later on in the disease pathway. The histopathological findings from tissue biopsy tend not to be diagnostic of pyoderma gangrenosum, but rather they are used as a process of excluding other diagnoses.

Diagnosis of Pyoderma Gangrenosum

The diagnosis of pyoderma gangrenosum still presents a challenge in the clinical environment for a number of reasons. Firstly, there are no specific parameters which have been accepted thus far as the official diagnostic criteria for pyoderma gangrenosum. Secondly, histology findings from the lesion are usually non-specific so are of limited use in terms of confirming diagnosis. Lastly, the list of potential differential diagnoses is vast, creating a higher chance of misdiagnosis. A recent article by Fletcher *et al.* [4] summarised three common criteria which are used in the diagnosis of pyoderma gangrenosum. The first well known tool was that of Su *et al.* (2004) [5], whereby the major criteria had to be fulfilled alongside two minor criteria to make a diagnosis of pyoderma gangrenosum. More recently between 2018 and 2019 however, two new diagnostic tools have been described. The first is the 'Delphi Consensus of International Experts diagnostic criteria [6]'. This has defined one major principle, which is necessary for diagnosis, based on biopsy results, as well as eight minor principles, of which only four need to be fulfilled. The second is the PARACELSUS score, which was developed with the aim of highlighting key symptoms and signs of pyoderma gangrenosum. It was developed and tested on 60 individuals who had previously had the condition and compared with 50 participants who had leg ulcers not attributed to pyoderma gangrenosum. All of these diagnostic criteria highlight the key features of a condition that was previously identified by diagnosis of exclusion.

It is important to note that currently the diagnosis of pyoderma gangrenosum can be made clinically, thus a biopsy is not considered a compulsory requirement for diagnosis as histological findings are not necessarily diagnostic [7]. Furthermore, as previously discussed, pathergy can play a role in the development of these necrotic lesions, therefore some hesitancy still exists when considering a biopsy, due to the risk of hastening the disease process through wound trauma.

Treating Pyoderma Gangrenosum

Randomised controlled trials and evidence surrounding the management of pyoderma gangrenosum is minimal and thus therapeutic intervention is largely based upon the magnitude of the pyoderma gangrenosum and is aimed at combatting the underlying inflammatory process. In general, treatment can be divided into topical treatment, systemic therapies (including the use of biologics), wound management, and symptom control [7]. From the literature available, it is evident that oral prednisolone and oral ciclosporin are amongst the commonly used systemic medications in pyoderma gangrenosum [8]. Biological therapies, such as infliximab, have demonstrated potential in management especially within the early stages of the disease, however there is a lack of substantial evidence in this realm. Wound management plays a key role in the healing process, but can vary significantly depending on the lesion itself e.g. where it is situated anatomically. Lastly, good symptom control including optimising analgesia and involvement of other specialty teams where appropriate, allows for a better healing process.

Patient Case Report

We report the case of a 46-year-old gentleman who was admitted to hospital following the development of a large sloughing, necrotic lesion on the left lower leg. The wound started off as a red papule which the patient tried to remove by puncturing it and coincided with a scratch from a rose thorn bush whilst gardening. However, over a three-week period it progressed into an exceptionally tender, deep ulcerated wound, rendering the patient unable to mobilise independently. He then developed two other lesions on his lower legs, which were similar in nature to the primary lesion, but markedly smaller in size. An important point to note is that when the principal lesion first arose, the patient reported a fever, and upon testing was found to be positive for coronavirus (COVID-19). Initially he was managed in the community with oral flucloxacillin, but due to the extent of skin breakdown and sloughing, alongside increasing tenderness, he was advised to seek emergency care.

On presentation to the emergency department, the patient denied any systemic symptoms. Apart from asthma, he had no other long-term medical conditions of note, and no previous reports of similar lesions. Observations including blood pressure, temperature and oxygen saturations were within the normal range and the primary lesion was swabbed. On examination, the principal wound on the left calf was deep and necrotic, actively bleeding, and had a distinct violaceous border with underlying erythematous skin, likely representing cellulitis (Figure 1). The two other lesions as previously described were smaller in size, but still exhibited sloughing and bleeding (Figure 2).

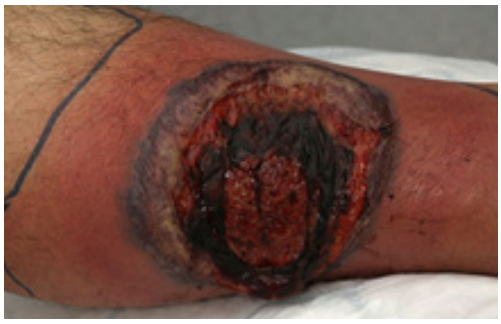

Figure 1

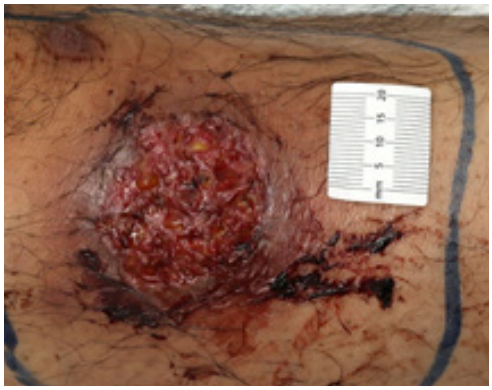

Figure 2

Investigations revealed a raised C-reactive protein at 250 mg/L (NR: 0.0 – 5.0), raised white cell count of 12.26 10^9 /L (NR: 4.0 – 11.0) and neutrophilia 7.90 10^9/L (NR: 2.0 – 7.5). Immunological markers demonstrated a positive p-ANCA and weakly positive epidermal intercellular antibodies. A wound swab of the left calf lesion grew Escherichia coli. The patient was commenced on intravenous flucloxacillin (2g 6-hourly) and clindamycin (600mg 6-hourly) as well as oral prednisolone (30mg once daily). The wound demonstrated improvement during admission, with reduction in inflammation and erythema. Apart from one spike in temperature on the day of admission, the patient remained well systemically and after seven days he was discharged with a two-week course of flucloxacillin, clindamycin and fucidin cream, alongside a tapering course of oral prednisolone. Upon discharge, he was referred to dermatology for outpatient follow-up and review. The patient reports significant healing and improvement of the wound since completing this course of treatment.

Discussion

Research and evidence suggests a variety of skin conditions that have been linked to coronavirus infection. Singh *et al.* (2020) [9] described six key categories of skin manifestations that have been linked to COVID-19 including morbilliform rashes, urticaria, chilblain-like rash and petechial rashes. McGonagle *et al.* (2021) [10] reported on the various vasculitis patterns seen with patients who have severe infection with COVID-19. Some patients were shown to present with pernio-like lesions, whilst others had "diffuse digital erythema." Interestingly, this report suggested that a small percentage of patients, who presented with skin-related disorders in the presence of coronavirus infection, had necrotic lesions. However, pyoderma gangrenosum was not specifically identified. Despite accounts of various cutaneous manifestations in relation to COVID-19, there are currently no official reports amongst existing literature that have identified an association between coronavirus infection and pyoderma gangrenosum. However, in the case report above we have highlighted a possible relationship between the two conditions.

Conclusion

In conclusion, from the current literature, pyoderma gangrenosum has been identified as a rare inflammatory condition whereby small papular lesions rapidly deteriorate and become necrotic, gangrenous wounds. Early identification is vital in appropriately managing this condition. Although there have been no reported links between pyoderma gangrenosum and COVID-19 so far, our case report demonstrates a possible connection between the two diseases.

References

1. Gavioli, Elizabeth M. Pyoderma Gangrenosum and Superimposed Infection: A Case Report. Advances in Skin & Wound Care. 2020 Jun; 33(6):1-3.
2. Schmieder SJ, Krishnamurthy K. Pyoderma Gangrenosum. [updated 2020 Jul 10].
3. George C, Deroide F, Rustin M. Pyoderma Gangrenosum – a guide to diagnosis and management. Clin Med. 2019 May; 19(3):224.
4. Fletcher J, Alhusayen R, Alavi A. Recent advances in managing and understanding pyoderma gangrenosum. Faculty Rev. 2019 Dec;8.
5. Su WPD, Davis MDP, Weenig RH, Powell FC, Perry HO. Pyoderma gangrenosum: clinicopathologic correlation and proposed diagnostic criteria. Int J Dermatol. 2004 Nov; 43(11):790-800.
6. Maverakis E, Ma C, Shinkai K, Fiorentino D, Callen JP et al. Diagnostic Criteria of Ulcerative Pyoderma Gangrenosum. JAMA Dermatol. 2018 Feb; 154(4):461-466.
7. Pompeo MQ. Pyoderma Gangrenosum Recognition and Management. Wounds. 2016 Jan; 28(1):7-13.
8. Brooklyn T, Dunnill G, Probert C. Diagnosis and treatment of pyoderma gangrenosum. BMJ. 2006 Jul; 333(7560):181-184.
9. Singh H, Kaur H, Singh K, Sen CK. Cutaneous Manifestations of COVID-19: A Systematic Review. Advances in Wound Care. 2020 Dec; 10(2).
10. McGonagle D, Bridgewood C, Ramanan A, Meaney JFM, Watad A. COVID-19 vasculitis and novel vasculitis mimics. Lancet Rheumatol. 2021 Jan. (20):30420-3.

Cite this article: Kinari Xina Patel MBChB, Mohammed S Al Abadie PhD FRCP (2021) Pyoderma Gangrenosum in the Presence of Coronavirus Disease (COVID-19). Japan Journal of Medical Science 2: 63-65.