

## Case Report

**Testicular Histoplasmosis Mimicking Malignancy in a Patient Infected by Human Immunodeficiency Virus (HIV)**Margaret Lie<sup>1</sup>, Kelsey Hummel<sup>1,2</sup>, Kristine McCluskey<sup>1,2</sup> and Ya Xu<sup>1,2\*</sup><sup>1</sup>Department of Pathology & Immunology, Baylor College of Medicine, Houston, TX 77030, United States<sup>2</sup>Department of Pathology, Ben Taub General Hospital, Houston, TX 77030, United States**\*Corresponding author**

Ya Xu (MD, PhD), Department of Pathology &amp; Immunology, Baylor College of Medicine, Ben Taub General Hospital, Houston, BCM 315, One Baylor Plaza, Houston, TX, 77030, United States

**Received:** 01 Feb 2021**Accepted:** 08 Feb 2021**Published:** 15 Feb 2021**Copyright**© 2021 Ya Xu (MD, PhD)  
OPEN ACCESS**Abstract****Introduction:** Human immunodeficiency virus (HIV) positive patients, specifically those who have progressed to acquired immunodeficiency syndrome (AIDS), are at risk for a number of opportunistic infections, such as disseminated histoplasmosis. We report a rare case of testicular histoplasmosis presenting as a solid testicular mass in a HIV positive patient.**Case Report:** A 60-year-old man with AIDS who has discontinued highly active antiretroviral therapy, treated latent tuberculosis, and history of disseminated histoplasmosis presented with a left scrotal mass. Serum alpha-fetoprotein, beta-human chorionic gonadotropin, and lactate dehydrogenase were negative. Ultrasound demonstrated a 5.9 cm left testicular mass. Radical orchiectomy was performed. Gross examination showed a 7.5 x 5.0 x 4.5 cm solid, yellow-tan, lobulated mass that replaced the testis with extensive necrosis and focal hemorrhage. Microscopically, there were large foci of necrosis with peripheral lymphohistiocytic infiltrates containing diffuse small yeasts within the histiocytes. Grocott-Gomori Methenamine-Silver stain highlighted numerous intracellular and extracellular narrow-based budding yeasts in the inflammatory infiltrates and necrotic areas. Acid-fast bacilli stain was negative. Compressed atrophic seminiferous tubules were only present at the peripheral of the testis. No malignancy was identified. A diagnosis of histoplasmosis was rendered.**Conclusion:** The differential diagnosis for a unilateral testicular mass in an immunocompromised patient is broad, and may include opportunistic infections, primary testicular malignancy and metastasis. Although systemic histoplasmosis involving testis is rare, the clinical history, gross specimen examination and morphological features of a testicular mass in a HIV-positive patient described here are very helpful to make the diagnosis of testicular histoplasmosis.**Keywords:** Histoplasmosis, Human immunodeficiency virus (HIV), Testicular mass**Introduction**Patients with untreated human immunodeficiency virus (HIV) are at an increased risk of acquiring opportunistic infections due to HIV-related immunosuppression. The condition of acquired immunodeficiency syndrome (AIDS) is usually defined as a CD4 cell count < 200 cells/ $\mu$ L or the presence of an AIDS-defining illness which includes several opportunistic infections. The fungal infections usually include histoplasmosis, cryptococcosis, coccidioidomycosis, and pneumocystis pneumonia (PCP) [1].In humans, histoplasmosis exists as two varieties with different causative organisms: *Histoplasma capsulatum* var. *capsulatum* (found in the Americas) and *H. capsulatum* var. *duboisii* (found in Africa) [2,3]. Histoplasmosis exists as a dimorphic fungi and is found as a mold in soils that contain bird or bat droppings [2]. Once the spores are inhaled, *H. capsulatum*

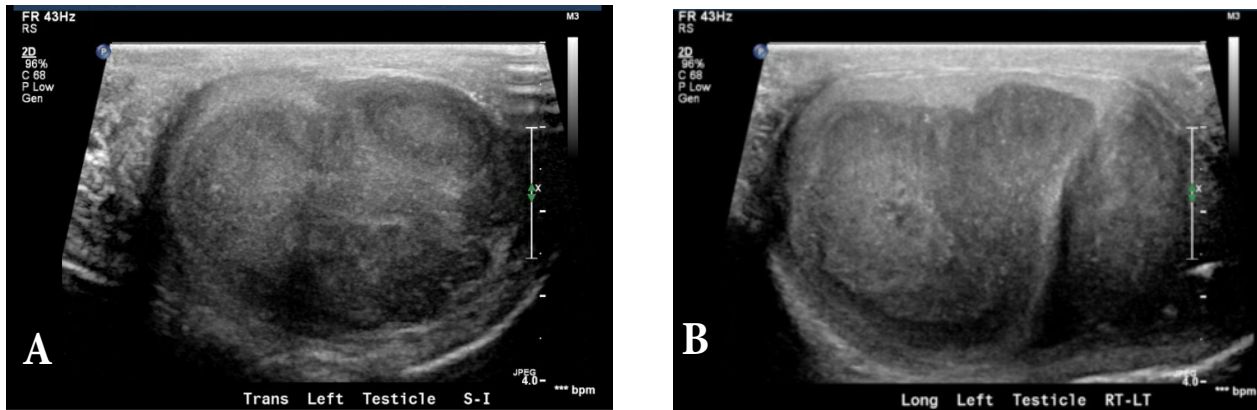
exists in yeast form in tissue. People who live around the Mississippi and Ohio River valleys in the United States are at risk of acquiring the fungus [4]. Most immune-competent individuals remain asymptomatic. In the immunocompromised or immunosuppressed host, clinical manifestations can occur. The main clinical manifestations are pulmonary related as acute pulmonary histoplasmosis, chronic cavitary pulmonary histoplasmosis, and granulomatous mediastinitis [2,5,6]. Infrequently, disseminated histoplasmosis can develop and can affect any organ, with most notably presents with symptoms of fever and weight loss [7]. Genitourinary system involvement is a rare phenomenon, and very few cases have been reported [2,8-10].

In this case report, we present a patient with a unilateral testicular mass found to be testicular histoplasmosis, a very unusual presentation of histoplasmosis with genitourinary tract involvement.

## Case Report

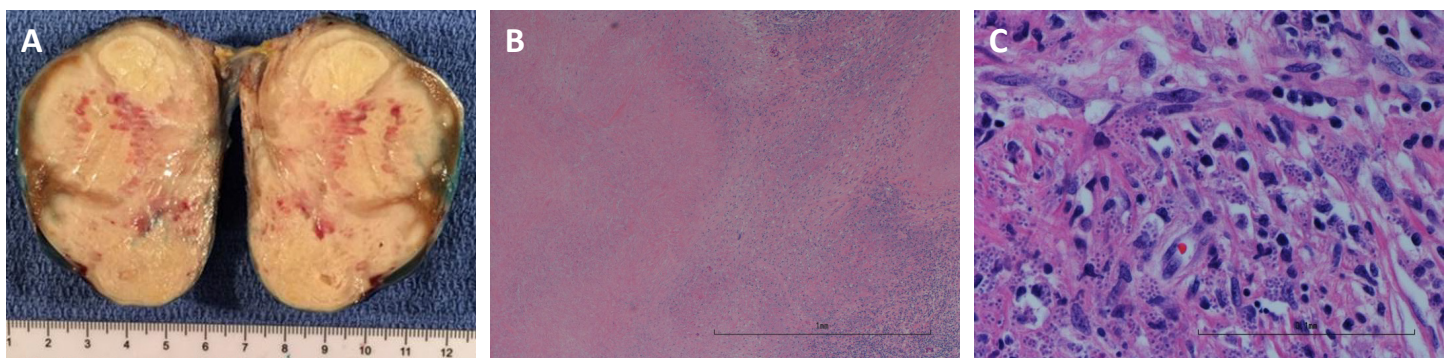
A 60-year-old Caucasian man with AIDS who had discontinued highly active antiretroviral therapy (HAART), untreated chronic hepatitis C, treated latent tuberculosis, and history of disseminated histoplasmosis (unclear the involved organs) presented to the emergency center of our institution with one week of diarrhea and non-bloody, non-bilious emesis associated with poor oral intake. The patient also had a 24-pound unintentional weight loss over one month and dysuria/suprapubic pain for several weeks. Physical examination revealed a firm and tender left testicle with scrotal enlargement. Ultrasonography of the left scrotum showed a heterogeneously infiltrative, and hypoechoic mass (5.9 x 3.1 x 4.4 cm) with peripheral hypoechoic satellite lesions (Figure 1). The ultrasound impression includes infection (possibly tuberculosis), primary testicular malignancy

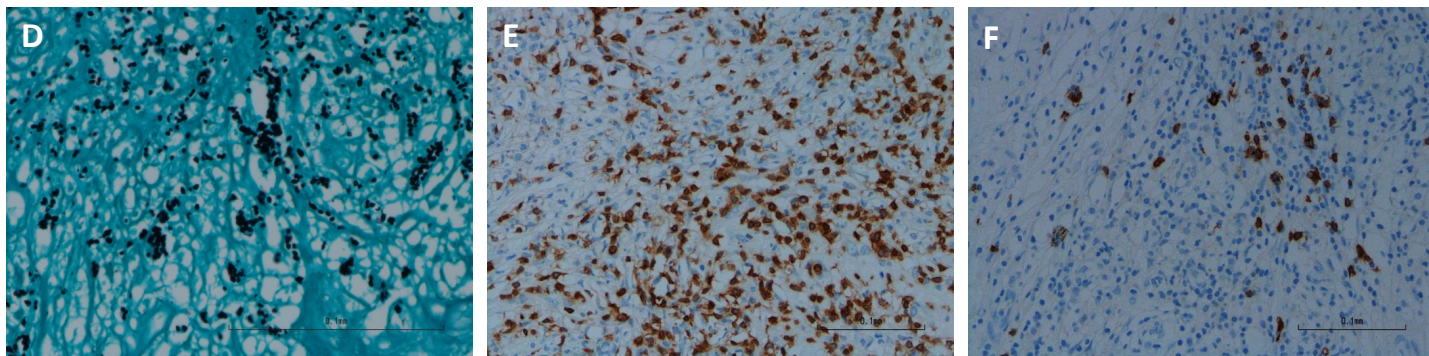
(including lymphoma), metastasis, or sequela of trauma. A computerized tomography (CT) scan of chest showed multiple nonspecific 2 to 5 mm solid pulmonary nodules scattered in bilateral lungs. CT of abdomen and pelvis revealed nonspecific thickening of the rectal mucosa. Labs were notable for hyponatremia, azotemia, acute kidney injury on chronic kidney disease, pyuria, bacteriuria, HIV-1 RNA 3,540 copies/ml and CD4 count of 80 cells/ $\mu$ L. Serum alpha-fetoprotein (AFP), beta-human chorionic gonadotropin (beta-hCG), and lactate dehydrogenase (LDH) were negative. Acid-fast bacilli (AFB) stain and culture of blood, cerebral spinal fluid (CSF), and feces for mycobacteria were negative. The patient's serum (10.81 ng/mL) and urine (>19 ng/mL) were positive for histoplasmosis antigen. Testing for other fungal and parasitic infections was negative. He started on itraconazole for treatment.



**Figure 1:** Ultrasonography of the left scrotum showed a heterogeneously infiltrative, and hypoechoic mass (5.9 x 3.1 x 4.4 cm) with peripheral hypoechoic satellite lesions in transverse (A) and longitudinal (B) views

The patient subsequently received left radical orchiectomy. On gross pathological examination, the left testis was 80-gram and bisected. The cut surface showed a 7.5 x 5.0 x 4.5 cm solid, lobulated, yellow-tan mass that entirely replaced the testis with extensive necrosis and focal hemorrhage (Figure 2A). Microscopic examination of the specimen revealed large foci of necrosis with peripheral lymphohistiocytic infiltrates and fibrosis on hematoxylin and eosin (H&E) stained sections (Figure 2B). There were diffuse histiocytes with intracellular small monotonous yeasts (Figure 2C). Grocott-Gomori Methenamine-Silver (GMS) stain highlighted numerous intracellular and extracellular narrow-based budding yeasts ranging 2-4  $\mu$ m in the inflammatory infiltrates and necrotic areas (Figure 2D). Acid-fast bacilli (AFB) stain was negative. Immunohistochemical stains displayed predominantly CD3-labeled T cells (Figure 2E), and scant CD20-labeled B cells (Figure 2F) in the lymphohistiocytic infiltrates. Compressed atrophic seminiferous tubules were only present at the peripheral of the testis (data not shown). No malignancy was identified. The findings are consistent with testicular histoplasmosis.





**Figure 2:** Gross examination of the left radical orchiectomy specimen and the histologic findings of the testicular histoplasmosis

- A. Left radical orchiectomy specimen showed lobulated necrosis and with satellite lesions in the peripheral of the testis.
- B. Hematoxylin and eosin (H&E) stain of the testicular mass displayed large foci of necrosis with peripheral lymphohistiocytic infiltrates and fibrosis at low power.
- C. H&E stain of the testicular mass showed intracellular yeasts within the histiocytes at high power.
- D. Grocott-Gomori Methenamine-Silver (GMS) special stain highlighted numerous narrow-based budding yeasts in the inflammatory infiltrates and necrotic areas.
- E. Immunohistochemical (IHC) stains displayed predominantly CD3-labeled T-cells in the lymphohistiocytic infiltrate.
- F. IHC displayed scant CD20-labeled B-cells in the lymphohistiocytic infiltrate.

The patient was found to have a 1.5 x 1 cm ulcer of the left posterior buccal mucosa status post left radical orchiectomy. Biopsy of the ulcer revealed squamous mucosa with histoplasmosis (data not shown), morphologically similar to that seen in left testis.

Due to the high histoplasmosis antigen level and disseminated presence of the organism, itraconazole was discontinued after three days, and amphotericin B was initiated along with pre-medication with hydrocortisone and meperidine. After two weeks of amphotericin B infusions, the patient was discharged with follow-up of nearly one year and half at present as an outpatient with lifelong itraconazole and anti-retroviral therapy.

## Discussion

The clinical presentation of our patient with chronic weight loss, dysuria, and suprapubic pain, and left testicular mass mimics a malignant process. Primary testicular tumors such as germ cell tumors usually occur in patients less than 45 years old [11]. In addition, negative testicular tumor markers (AFP, beta-hCG, LDH) decrease the likelihood of primary testicular germ cell tumor. Primary testicular lymphoma is usually seen in elderly patients, and cannot be excluded clinically in this 60-year-old patient. Infection should be considered in this HIV-positive patient with discontinuation of HAART therapy and with a past medical history of tuberculosis and histoplasmosis. The lab results of positive histoplasmosis antigen in serum and urine raise the possibility of testicular histoplasmosis.

The gross pathological findings of the large testicular mass with extensive necrosis cannot narrow down the differential diagnosis mentioned above, mainly malignancy and infection. Large foci of necrosis with peripheral lymphohistiocytic infiltrates are the morphological appearance microscopically. Necrosis with lymphohistiocytic infiltrates can be seen in testicular tuberculosis, which accounts for 3% of all cases of genital tuberculosis [12,13] and has been known to mimic testicular tumors [14]. The lack of well-defined necrotizing granuloma, and negative AFB stain in our case have ruled out testicular tuberculosis. Necrosis with lymphohistiocytic infiltrates can also be seen in primary lymphoma of testis. There are significantly more T cells than B cells demonstrated by immunohis-

tochemistry, supportive of an inflammatory/reactive process rather than a lymphoproliferative disorder. There are numerous intracellular and extracellular small yeasts on H&E stain under high power examination. The organisms are clearly highlighted by GMS special stain, morphologically consistent with *Histoplasma capsulatum*.

Systemic histoplasmosis with genitourinary tract involvement is rare. The common sites are kidney and adrenal glands, followed by penis, prostate, epididymis, and testis [2,9,10,15]. There is total six cases of testicular histoplasmosis found in the literature by searching PubMed [15-20]. There is one case of testicular histoplasmosis out of 19 cases of disseminated histoplasmosis in a study of autopsy cases in Venezuela published in 1970 [19]. One case of testicular histoplasmosis is described in a series of 102 cases of disseminated histoplasmosis from 1932 to 1978 collected from the files of hospitals in Nashville, serving the highly endemic area [20]. The side of the involved testis is not indicated in these two studies. In other four cases reported as case report, the age range of patients are from 38 to 70 years old, and all these patients have the treatment of left orchiectomy due to left scrotal swelling/testicular mass (4.5 to 6.5 cm). Our case has the largest size of testicular mass, 7.5 cm. There is one reported case with the patient diagnosed of disseminated histoplasmosis at autopsy two years after the orchiectomy specimen misdiagnosed as abscess and granuloma [18]. Our patient and a previously reported patient have similar findings [16]. Both are untreated HIV-positive patients with chronic left scrotal swelling, weight loss, and an elevated urine histoplasmosis antigen. Both cases have histiocytic inflammation with intracellular yeast forms. In the reported case, the inflammatory infiltrates are in the interstitium between seminiferous tubules with extension to epididymis. The testis in the current case is largely replaced by necrosis and inflammatory infiltrates with both intracellular and extracellular yeast forms. There is only a very thin rim of atrophic seminiferous tubules at periphery with no recognizable epididymis. Histological examination under high power, searching for small yeasts (2-4  $\mu$ m) on H&E stain, with visualization by GMS stain, is crucial for the diagnosis of testicular histoplasmosis.

Our patient has a past medical history of histoplasmosis and newly diagnosed testicular histoplasmosis and gingival histoplasmosis. It is unclear

the prior involved organ(s) of this patient, and it is unknown if the small nodules in the bilateral lungs on CT of chest are representative of the old infection of histoplasmosis or not. No biopsy has been done to further evaluate the nonspecific thickening of rectal mucosa shown on imaging in this patient. There are five cases of gingival histoplasmosis found in a study of 102 case of disseminated histoplasmosis reported previously [20]. Reactivation of latent histoplasmosis can occur in immunocompromised patients [7].

The antifungal treatment in our patient includes itraconazole, and amphotericin B. Itraconazole is in use for the treatment of mild and moderate histoplasmosis, and amphotericin B for moderate-to-severe or disseminated infections. The treatment of testicular histoplasmosis may need surgical intervention followed by systemic antifungals for at least one year [21].

## Conclusion

The differential diagnosis of a unilateral infiltrative testicular mass in an immunocompromised patient is broad, and may include infection, primary testicular malignancy, or metastasis. Integration of the clinical findings, awareness of the mass effect, and recognition of the morphological features of histoplasmosis described here are the key steps for making the correct diagnosis of testicular involvement in disseminated histoplasmosis.

## Conflict of Interest

None of the authors have any financial interest or conflicts of interest.

## Acknowledgements

No additional acknowledgements.

## References

1. Selik, Richard M, Mokotoff, Eve D, Branson B, et al. (2014) Revised Surveillance Case Definition for HIV Infection. *Morb Mortal Wkly Rep* 63: 29-31.
2. Kauffman CA (2007) Histoplasmosis: a clinical and laboratory update. *Clin Microbiol Rev* 20: 115-132.
3. Kasuga T, Taylor JW, White TJ (1999) Phylogenetic relationships of varieties and geographical groups of the human pathogenic fungus *Histoplasma capsulatum* darling. *J Clin Microbiol* 37: 653-663.
4. Manos NE, Ferebee SH, Kerschbaum WF (1956) Geographic variation in the prevalence of histoplasmin sensitivity. *Dis Chest* 29: 649-668.
5. Goodwin RA, Loyd JE, Des Prez RM (1981) Histoplasmosis\_in\_Normal\_Hosts. 1. *Medicine (Baltimore)* 60: 231-266.
6. Goodwin RA, Owens FT, J, Snell JD, Hubbard WW, Buchanan RD, et al. (1976) Chronic pulmonary histoplasmosis. *Medicine (Baltimore)* 55: 413-452.
7. Wheat LJ, Connolly-Stringfield PA, Baker RL, et al. (1990) Disseminated histoplasmosis in the acquired immune deficiency syndrome: clinical findings, diagnosis and treatment, and review of the literature. *Medicine (Baltimore)* 69: 361-374.
8. Randhawa HS, Chaturvedi S, Khan ZU, Chaturvedi VP, Jain SK, et al. (1995) Epididymal histoplasmosis diagnosed by isolation of *Histoplasma capsulatum* from semen. *Mycopathologia* 131: 173-177.
9. Baig WW, Attur RP, Chawla A, Reddy S, Pillai S, et al. (2011) Epididymal and prostatic histoplasmosis in a renal transplant recipient from southern India. *Transpl Infect Dis* 13: 489-491.
10. Friskel E, Klotz SA, Bartholomew W, Dixon A (2000) Two unusual presentations of urogenital histoplasmosis and a review of literature. *Clin Infect Dis* 31: 189-191.
11. Howlader N, Noone AM, Krapcho M, Miller D, Breast A, et al. (2020) *Cancer Statistics Review, 1975-2017 - SEER Statistics*. Bethesda Pg 1-19.
12. Viveiros F, Tente D, Espiridião P, Carvalho A, Duarte R (2009) Tuberculose testicular: Caso clínico. *Rev Port Pneumol* 15: 1193-1197.
13. Jumbi T, Mugo R, Onkunya L, Mwendu C, Osawa F, et al. (2019) Testicular tuberculosis can mimic a testicular tumor. *J Pediatr Surg Case Reports* 41: 43-45.
14. Shugaba AI, Rabiou AM, Uzokwe C, Matthew RM (2012) Tuberculosis of the testis: A case report. *Clin Med Insights Case Reports* 5: 169-172.
15. Botero-García CA, Faccini-Martínez AA, Uribe E, Calixto OJ, Pérez-Díaz CE, et al. (2017) Epididymo-orchitis caused by *Histoplasma capsulatum* in a colombian patient. *Rev Soc Bras Med Trop* 50: 868-870.
16. Tichindelean C, East JW, Sarria JC (2009) Disseminated histoplasmosis presenting as granulomatous epididymo-orchitis. *Am J Med Sci* 338: 238-240.
17. Schuster TG, Hollenbeck BK, Kauffman CA, Chensue SW, Wei JT (2000) Testicular histoplasmosis. *J Urol* 164: 1652.
18. Monroe M (1974) Granulomatous orchitis due to *Histoplasma capsulatum* masquerading as sperm granuloma. *J Clin Pathol* 27: 929.
19. Salfelder K, Brass K, Doehnert G, Doehnert R, Sauerteig E (1970) Fatal disseminated histoplasmosis: anatomic study of autopsy cases. *Virchows Arch A Pathol Anat* 350: 303-335.
20. Goodwin RAJ, Shapiro JL, Thurman GH, Thurman SS, Des Prez RM (1980) Disseminated histoplasmosis: clinical and pathologic correlations. *Medicine* 59: 1-33.
21. Wheat LJ, Friefeld AG, Kleiman MN, et al. (2007) Clinical practice guidelines for the management of patients with histoplasmosis: 2007 update by the Infectious Diseases Society of America. *Clin Infect Dis* 45: 807-825.

**Cite this article:** Margaret Lie, Kelsey Hummel, Kristine McCluskey and Ya Xu (2021) Testicular Histoplasmosis Mimicking Malignancy in a Patient Infected by Human Immunodeficiency Virus (HIV). *Archives of Clinical Case Reports* 2: 152-155.

**Copyright:** ©2021 Ya Xu (MD, PhD). This is an open-access article distributed under the terms of the Creative Commons Attribution License, which permits unrestricted use, distribution, and reproduction in any medium, provided the original author and source are credited.